

Proliferative Vitreoretinopathy

Proliferative vitreoretinopathy (PVR) is defined as the “growth of membranes on both surfaces of the detached retina and on the posterior surface of the detached vitreous gel.”

From: [Ocular Disease, 2010](#)

Related terms:

[Vitreotomy](#), [Retinal Detachment](#), [Retinal Pigment Epithelium](#), [Vitreous](#), [Silicone Oil](#), [Retinal](#), [Iris](#)

[View all Topics](#)

Proliferative vitreoretinopathy

Clyde Guidry, in [Ocular Disease](#), 2010

Clinical background

Proliferative vitreoretinopathy (PVR) is defined as the “growth of membranes on both surfaces of the [detached retina](#) and on the posterior surface of the detached vitreous gel.” The name was introduced in 1983 by the Retina Society Terminology Committee¹ as part of a classification scheme for a group of intraocular complications previously known by more descriptive terms, including “massive vitreous retraction,” “massive preretinal retraction,” and “massive periretinal proliferation.” PVR is not a distinct disease per se, but is instead a complication common to a variety of clinical disorders. It is most prevalent as a clinical complication of surgical procedures to correct [rhegmatogenous retinal detachments](#), which are detachments that follow formation of a [retinal tear](#) or hole. Tractional forces generated within the scar tissue-like PVR membranes can be transmitted to the retina and cause complete [retinal detachment](#), [retinal degeneration](#), and permanent blindness.

[> Read full chapter](#)

Proliferative Vitreoretinopathy

P. Hiscott, D. Wong, in [Encyclopedia of the Eye](#), 2010

Proliferative vitreoretinopathy (PVR) is the major cause of failure of [retinal detachment](#) surgery. It is manifest by the formation of fibrocellular membranes on the retinal and posterior hyaloid surfaces. Most cells in PVR membranes originate from adjacent retina and the displaced cells synthesize much of the membrane matrix. The membranes have some features in common with healing wounds. For example, they are contractile and thus tend to cause (re)detachment, folding, and/or tearing of the retina. Treatment requires microsurgical membrane removal. Nevertheless, pharmacological targeting of key membrane cell activities is a promising route for disease prevention in high-risk retinal detachment patients.

[> Read full chapter](#)

Pathogenesis of Proliferative Vitreoretinopathy

Peter Wiedemann, ... Yusheng Wang, in [Retina \(Fifth Edition\)](#), 2013

Introduction

[Proliferative vitreoretinopathy](#) (PVR) is a complex cellular reaction representing a vitreoretinal wound-healing response that results in a characteristic clinical appearance. PVR can be induced by diverse events including rhegmatogenous [retinal detachment](#), surgical intervention, or trauma.

PVR is reported to have an incidence of 5–10% of all rhegmatogenous retinal detachments (RRD),¹ and it is believed to be the most common cause of ultimate failure of a surgery for RRD. A high rate of PVR has also been reported following posterior segment procedures or disorders such as giant [retinal tears](#), macular relocation surgery, endoresection of tumors and chip implantation. In human immunodeficiency, virus-infected patients PVR has been developed in 29% of [cytomegalovirus](#) retinitis-related retinal detachment.² In children, postoperative PVR occurs in higher incidence and is characterized by a rapid and aggressive development.³ PVR is also a common complication following a variety of ocular injuries with the highest frequency after perforating and penetrating wounds, in which the incidence is 10–45%.

Soon after the development of [vitrectomy](#), PVR became a specific indication for vitreous surgery. The changing understanding of PVR [pathogenesis](#) is reflected in the different classification systems. In the beginning, it was assumed to be primarily due to changes in the vitreous gel (“massive vitreous retraction”, “massive prereti-

nal retraction”). Then the involvement of cells was recognized, and the condition was re-termed “massive periretinal proliferation.”⁴ Later, a distinct biomicroscopic classification was developed in an attempt to categorize the severity of the [disease \(Retina Society Classification 1983\)](#). A major problem of the latter system was that it did not reflect prognosis and surgical difficulty. The Cologne classifications and the [Silicone Oil Study classification](#)⁶ took these aspects into account by separating anterior and posterior PVR. The updated Retina Society classification is a compromise, which describes severity (A, B, C), localization, updated grade, and updated contraction type.⁷ However, this classification still does not consider many aspects of the disorder. Therefore, a classification that provides additional relevant clinical information, such as the evolutionary stages of the disease (biologic activity) and the degree of surgical difficulty is desirable.⁸

Clinically, early stages of PVR are characterized by an increased reflectance and a [cellophane](#) appearance of the inner retinal surface. Additionally, tortuosity of both small and larger vessels is regularly observed. The pathological hallmarks of the advanced PVR include periretinal membrane formation, causing development of surface wrinkling and single or multifocal star-folds (Fig. 97.1). In the final stages, multidirectional tractional forces produced by posterior and/or anterior PVR form a narrow or closed funnel of the detached retina.⁹

A [retinal break](#) is a prerequisite for the development of PVR. Almost all risk factors for the PVR are associated with intravitreal dispersion of [retinal pigment epithelial \(RPE\)](#) cells or the breakdown of the [blood–retinal barrier \(BRB\)](#).^{10,11} The size of breaks, the extent of detachment, the presence of preoperative inflammation or low-grade PVR, and [iatrogenic complications](#) are important factors in the pathogenesis of severe PVR after the surgery for retinal detachment.^{12,13}

Several investigators have underlined the parallels between PVR and the general wound-healing process.^{14,15} PVR develops in a sequence of three overlapping phases: inflammation, [cellular proliferation](#), and [extracellular matrix](#) remodeling. The time course of PVR development is poorly investigated. Data which were accumulated from clinical analysis could reveal that on average it takes 4–8 weeks for PVR development after surgery.^{8,16} Detailed PVR [chronobiology](#) was evaluated in the experimental animal model of PVR induced by macrophages. The inflammation phase is initiated immediately in response to macrophage injection. Cellular proliferation can be detected as early as days 4 ± 7 and peaks on days 10 ± 14 . The scarring-induced retinal detachment occurs during the 2nd and 3rd weeks after macrophage injection.¹⁷

[> Read full chapter](#)

Proliferative Vitreoretinopathy

Ian J. Constable, Manish Nagpal, in [Retina \(Fifth Edition\)](#), 2013

Introduction

[Proliferative vitreoretinopathy](#) (PVR) is the clinical syndrome associated with retinal [traction](#) and detachment in which cells with proliferative potential multiply and contract on retinal surfaces and in the vitreous compartment.^{1–4} PVR presents with a spectrum of severity ranging from subtle retinal wrinkling, to fixed folds and tears with rolled edges and to total rigid [retinal detachment](#), retinal shortening and advanced periretinal proliferation (Figs 107.1, 107.2). PVR is the most common cause of failure in retinal detachment surgery. It can occur in untreated eyes with retinal detachment, especially with [vitreous hemorrhage](#), or after [cryotherapy](#) or even laser [retinopexy](#), pneumatic retinopexy, [scleral buckling](#) or [vitrectomy](#) and after a variety of [surgical complications](#). It is common after penetrating injuries and a variety of conditions associated with prolonged inflammation. Although surgical reattachment of retinas associated with PVR can now be achieved in most cases, visual results remain disappointing. Therefore, prevention through early recognition of risk factors and subtle signs of PVR and appropriate modification of standard surgical techniques for retinal detachment remain all-important. Some degree of PVR is found in up to 10% of retinal detachments.^{5–7} If PVR is progressive and [macula](#) reattachment delayed, then despite complex surgery, low vision is the result in the majority of eyes.

[> Read full chapter](#)

Progress and Prospects in Ocular Gene Therapy

XUYANG LIU, ... PAUL L. KAUFMAN, in [Ocular Therapeutics](#), 2008

4 Proliferative vitreo-retinopathy (PVR)

PVR is a vision-threatening complication of rhegmatogenous retinal detachment or severe ocular trauma (intraocular foreign body, penetration, perforation, contusion, or rupture). It is known that [retinal pigment epithelial](#) (RPE) cells possess the potential to transdifferentiate into [myofibroblasts](#) after stimulation with [transforming growth factor \$\beta\$](#) (TGF β), and are implicated in the pathogenesis of PVR. In fact, almost all known risk factors for PVR are associated with intravitreal dispersion of

RPE cells. In addition, RPE cells are a major cellular component of PVR membranes (Nagasaki *et al.*, 1998; Schubert *et al.*, 1997). Schubert *et al.* (1997) demonstrated that retroviral-mediated transfer of the herpes simplex virus-thymidine kinase (HSV-tk) gene into RPE cells in culture followed by [ganciclovir](#) treatment induced a significant inhibition of cell growth, suggesting that retrovirus-mediated suicide gene therapy might be a feasible gene therapy strategy for PVR. As an alternative strategy, a ribonucleotide-reductase-deficient HSV type I (HSV-I) mutant hrR3 can destroy proliferating RPE cells in culture and might be useful for treating PVR (Wong *et al.*, 1999).

Previous studies have suggested that growth factors expressed by the cells (primarily RPE cells) in the PVR epiretinal membrane, such as [platelet-derived growth factor](#) (PDGF), contribute to PVR in experimental models of the disease, as well as in humans. The *in vivo* and *ex vivo* studies by Ikuno and Kazlauskas (2002) showed that retrovirus-mediated dominant negative aPDGFR expression was effective in attenuating PVR in a rabbit model of the disease. PVR pathogenesis also includes a fibrotic reaction by RPE cells and other retinaderived non-neural cells. [p38 Mitogen-activated protein kinase](#) (MAPK) plays a role in TGF β -2-mediated enhancement of the fibrogenic reaction in a human RPE cell line, ARPE-19. Gene transfer of a dominant negative (DN)-p38MAPK attenuated the post-retinal detachment fibrotic reaction of the RPE cells *in vivo* in mice, suggesting that this might be an effective therapeutic approach in treating PVR (Saika *et al.*, 2005).

[> Read full chapter](#)

Surgical Retina

John T. Thompson, in [Retina \(Fourth Edition\)](#), 2006

PVR after hemorrhagic choroidal detachment

PVR that develops in eyes with hemorrhagic [choroidal detachment](#) or expulsive hemorrhage is especially difficult to manage. Hemorrhagic [choroidal detachments](#) most frequently develop as a [complication of cataract surgery](#) but may develop during virtually any intraocular procedure or rarely develop as a complication of trauma. The presence of subretinal blood seems to potentiate the development of PVR, and incarceration of vitreous or retina in the corneal incision provides the [traction](#) necessary to lead to [retinal breaks](#). PVR usually develops at least several weeks after the onset of the choroidal detachment. The hemorrhagic choroidal detachment often takes 1 to 3 weeks to liquefy, and liquefaction is desirable before repair of the rhegmatogenous [retinal detachment](#) is attempted. The treatment

of PVR must include drainage of the hemorrhagic choroidal detachments, if still present, in addition to relief of traction and closure of retinal breaks. Avoidance of periods of hypotony during the surgical procedure for PVR is important, since the hemorrhagic choroidal detachment may recur. Broad circumferential [scleral buckles](#) may produce serous choroidal detachments in these eyes.

[> Read full chapter](#)

Retinal detachment and proliferative vitreoretinopathy

Oh Woong Kwon MD, PhD, ... Ji Hun Song MD, in [Retinal Pharmacotherapy](#), 2010

INTRODUCTION

[Proliferative vitreoretinopathy](#) (PVR) is a disease entity related to a number of intraocular diseases, including [retinal detachment](#) (RD). Several studies have confirmed the hypothesis that PVR occurs as a reparative process induced by [retinal breaks](#) and excessive inflammatory reaction. A survey of recently published series suggested that the frequency of PVR remains largely unchanged in primary RD, with the incidence ranging from 5.1 to 11.7%.¹ PVR is the most common cause of failed repair of rhegmatogenous RD and risk factors for PVR are related to several, well-known pre-, intra-, and postoperative clinical situations. Currently, surgery such as pneumatic [retinopexy](#), [scleral buckling](#), and [pars plana vitrectomy](#) (PPV) is the mainstream [therapeutic modality](#) for RD and PVR. The goal of surgery is to create chorioretinal adhesion around all the retinal breaks and to relieve all the tractional force. Single-operation reattachment rates were 73% for pneumatic retinopexy and 82% for scleral buckling after 6 months, and multiple-operation reattachment rates at 2 years were 99% for pneumatic retinopexy and 98% for scleral buckling for RD. Surgical success rates for PVR have improved as techniques and instruments of vitrectomy evolved. The introduction of ancillary techniques such as longer-acting gases and long-term vitreous substitutes like [silicone](#) oil elevated the success rate from 35–40% to approximately 60–75% at 6 months. Despite these advances, more than one-fourth of initially successful cases results in redetachment due to recurrent retinal [traction](#). Furthermore, visual results are less satisfactory and only 40–80% of cases with anatomic success achieve ambulatory vision. As a result, PVR remains a difficult problem to manage and continuing efforts have been made to develop other forms of therapy to inhibit the pathologic response causing traction. Recent efforts have been directed toward the chemical inhibition of cellular proliferation and membrane contraction in PVR.

> [Read full chapter](#)

Epigenetics in Ocular Medicine

V.F. Oliver, ... S.L. Merbs, in [Medical Epigenetics](#), 2016

Proliferative Vitreoretinopathy

Proliferative vitreoretinopathy (PVR) is a severe complication of retinal detachment, and is the most common reason for failure in its surgical treatment. PVR occurs as the newly exposed RPE cells respond to cytokines in the vitreous, causing formation of fibrotic membranes via proliferation and [epithelial–mesenchymal transition \(EMT\)](#) (Fig. 22.2). Vision loss occurs when the fibrotic membranes contract, resulting in further retinal detachment.

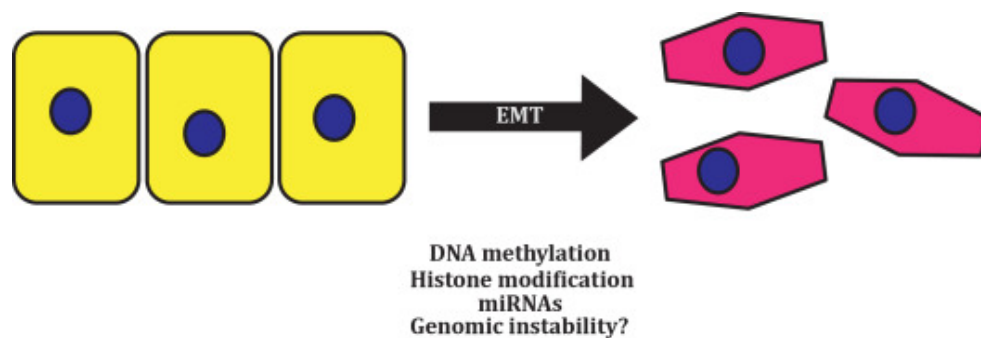


Figure 22.2. Epithelial–mesenchymal transition (EMT). During EMT epithelial cells lose cell-to-cell adhesion and undergo transdifferentiation to mesenchymal cells. Mesenchymal cells are a type of stem cell and possess proliferative properties. For this reason, EMT is a common event in cancer and other proliferative diseases.

As the EMT process is an important component of PVR pathogenesis, miRNAs that regulate differentiation of RPE cells may be utilized as potential therapies to prevent PVR. The miR-204/211 miRNAs are regulated by [MITF](#), a key regulator of RPE differentiation, and are highly expressed in the RPE suggesting they may be good candidates for therapy [68]. Additional candidate miRNAs include miR-34a, which regulates proliferation and migration of RPE cells by downregulating [MET](#) [61,69], and miR-29b, which regulates [transforming growth factor \$\beta\$](#) (TGFB)—an important cytokine in fibrotic diseases, which has been implicated in the induction of PVR fibrosis [70]. The [histone](#) deacetylase inhibitor TSA is known to affect EMT [71]. In RPE cells, TSA inhibited proliferation and prevented TGFB-induced EMT by regulating both the canonical and noncanonical pathways [72], suggesting novel therapeutic interventions for PVR prevention. (Table 22.3).

Table 22.3. Summary of Epigenetic Modifications Described in Proliferative Vitreoretinopathy

miRNA	miR-204/211 [68], miR-34a [61,69], miR-29b [70]
-------	---

[> Read full chapter](#)

Breakdown of the Retinal Pigmented Epithelium Blood–Retinal Barrier☆

M. Elizabeth Hartnett, in [Reference Module in Neuroscience and Biobehavioral Psychology](#), 2017

Proliferative Vitreoretinopathy

Proliferative vitreoretinopathy (PVR) occurs when cellular contractile membranes develop on the surface of the retina and contract it and pull open breaks in the retina, which can lead to complex [retinal detachments](#). It is the most common cause of failed retinal detachment repair. Vitreous fluorophotometry readings in animal models of PVR show a breakdown in the BRB associated with released cells into the vitreous cavity. It is believed that RPE cells, serum, and other factors have access to the vitreous cavity and are responsible for further breakdown of the BRB and growth of preretinal membranes.

The treatment for PVR, currently, is surgical, requiring vitrectomy and stripping of the membranes from the retina, and then methods to reattach the retina and create a permanent chorioretinal adhesion. However, ongoing research may provide medical means to prevent the formation of preretinal membranes.

[> Read full chapter](#)